


- Case Report: Kovax the Wonder Dog
- News & Notes
- Continuing Education Dinner:  
New Approaches to Old Problems

## Surgeons Expand VetCare's Specialty Services



*We are pleased to announce our affiliation with Veterinary Surgical Centers of the Delta. Together we now offer comprehensive veterinary services utilizing the most up-to-date diagnostic techniques and treatments. When your pet is cared for with our group you can be assured that there is always a doctor present (continuity of patient care) and that specialists are always on-call and available for situations which may require immediate attention.*

### **John J. Haburjak, DVM**



Dr. John Haburjak graduated from UC Davis Veterinary School in 1993. He practiced in Northern California for five years before returning to academics to complete a combined surgical residency program in San Diego and the University of Illinois.

Dr. Haburjak is a Diplomate of the American College of Veterinary Surgeons. He has presented at several annual conferences, including the Veterinary Orthopedic Society and AVORE. His clinical surgical interests include surgical oncologic procedures of the face, head and

neck, corrective orthopedic procedures and neurosurgery (spinal).

Dr. Haburjak's hobbies include SCUBA diving, Oakland A's baseball, road cycling and cooking (not to mention eating, too!). He shares his life with his wife, Aimee (also a veterinarian), daughter Eva, Calvin (many-toed, Siamese cross) and Noelle (a Cavalier King Charles Spaniel).

### **Gregory S. Marsolais, DVM, MS**



Dr. Gregory S. Marsolais is from Sacramento and received his Master of Science and Doctor of Veterinary Medicine degrees in 2002 from Iowa State University. He completed his surgical residency at the University of Illinois in 2006 and in July of 2006, Dr. Marsolais helped to found Veterinary Surgical Centers of the Delta and became chief of surgical staff at the Dublin practice. His professional interests include neurologic surgery including spinal fractures and intervertebral disk ruptures, orthopedic surgery including joint surgery, fracture repair, and arthroscopy, and general soft tissue surgery.

In his spare time, Dr. Marsolais enjoys training for and completing marathons, travel, and SCUBA diving. He is accompanied by one cat ("Diz" which is short for Dizzy — she has a vestibular disorder).

### **Kimberly Carlson, DVM**



Dr. Kimberly Carlson graduated from the University of Illinois School of Veterinary Medicine in 2001. After receiving her Doctor of

Veterinary Medicine degree she completed a one year rotating internship in small animal medicine and surgery at The Animal Medical Center in New York and then a one year specialty internship in small animal surgery at The Dallas Veterinary Surgical Center in Texas. Dr. Carlson completed a three year surgery residency at Tufts University Cummings School of Veterinary Medicine in New England. After a great deal of travel she finally calls northern California home.

Dr. Carlson's clinical interests include orthopedic surgery such as the tibial tuberosity advancement (TTA), tibial plateau leveling osteotomy (TPLO), triple pelvic osteotomy (TPO) and total hip implant procedure, as well as neurosurgery, and urogenital surgery.

Dr. Carlson's personal interests include SCUBA diving, running, and weight training. In addition she is an avid and knowledgeable collector of antique and vintage posters, especially film noir and science fiction. She has a love of German shepherds and lives with her old schutzhund competition dog, Christian and two cats named Butch and Jacques.

# Kovax the Wonder Dog

On July 11<sup>th</sup> 2006, when Kovax, an eight year old MN Labrador Retriever decided to hop the fence of his family's backyard and wander around the neighborhood, he never realized the trouble he would get into. He also did not realize that he would represent the inaugural patient treated through the synergy created by combining the VetCare emergency medical service, VetCare internal medicine practice, and the Veterinary Surgical Centers of the Delta at VetCare.

Kovax had been hit by a car, and on presentation was tachycardic (HR 180) and stuporous, with poor pulses, and shallow breathing. SpO<sub>2</sub> was 94% on room air and his systolic blood pressure was 84 mm. Initial PCV was 40% and TP was 5.6g/dL. He had bilateral epistaxis and was in shock. Dr. Cheryl Ramos wasted no time in initial assessment and emergency treatment of shock with IV crystalloids and colloids, and oxygen therapy. Initial assessment suggested a right side coxofemoral luxation as well as a right sided scapular fracture, rendering Kovax unable to ambulate or stand.

Client counseling was performed regarding his polytraumatic fractures and head trauma and the owners elected to move forward with therapy. The first 12 hours found Kovax' mentation was worsening. Solu-medrol, mannitol and lasix therapy was implemented for cerebral edema. Analgesia was initiated as mentation improved with hydromorphone and a fentanyl patch. Radiographs confirmed the diagnosis of a comminuted scapular fracture and coxofemoral luxation on the right side (see Fig. 1 and 2).

By morning, Kovax was transferred into Dr. Barry Kipperman's care for on-

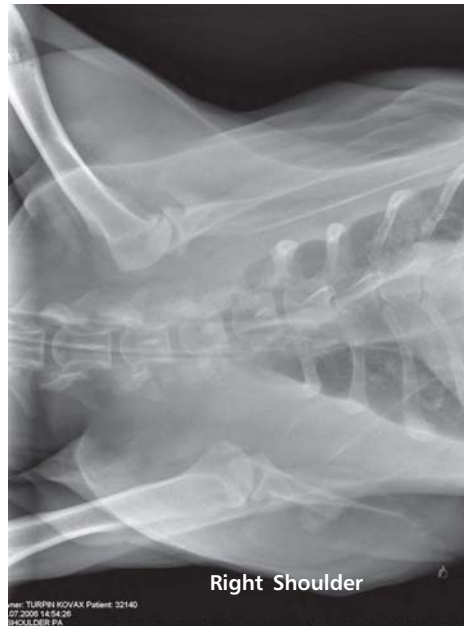

Figure 1

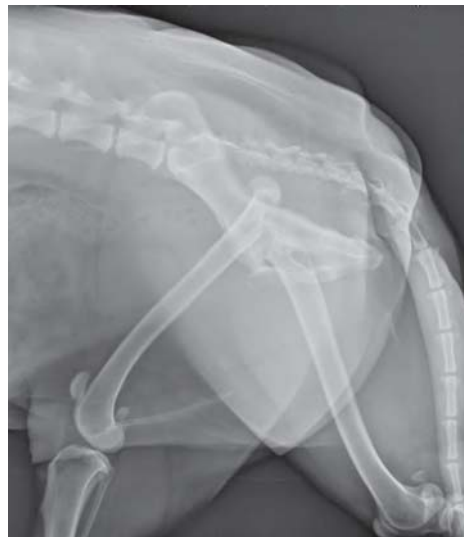

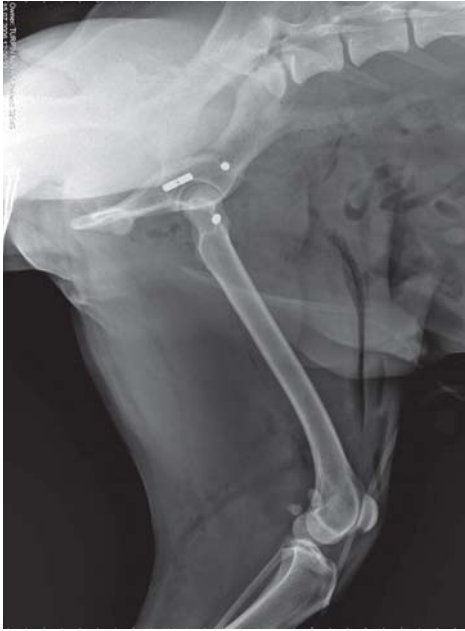Figure 2

going therapy. A urine collection system was placed to ensure adequate urine output and for ease of nursing care due to his non-ambulatory status. Paroxysmal ventricular premature contractions with heart rates in excess of 230 beats/min were noted with continuous EKG

monitor. As the arrhythmias had no hemodynamic impact, anti-arrhythmic therapy was not initiated. Therapy was largely supportive until mid-day when the PCV reached 19% with a TP of 3.5 and Kovax received a blood transfusion. With the assistance of Dr. Kipperman during the day and Dr. Gerardo Martin del Campo in the evening he continued to improve over the next 48 hours until his cardiovascular, neurologic, and hematologic systems were nearly completely stable. Kovax remained a recumbent animal, now with normal mentation and a willingness to stand. His right sided orthopedic problems prevented this and the plan included open reduction and stabilization of the coxofemoral luxation. An open reduction was deemed necessary to provide Kovax the best opportunity to bear weight immediately on his paretic right side.

On day four of hospitalization, Kovax became the first surgical case operated by the newly formed Veterinary Surgical Centers of the Delta. Dr. John Haburjak performed an open reduction and stabilization of the coxofemoral luxation with a toggle pin and anti-rotational suture (see Fig. 3). By the following morning Kovax was significantly more comfortable and was ambulatory on his right hind limb. His appetite had returned and he was discharged on day six to continue his recovery at home on pain management, antibiotics and sling walking.

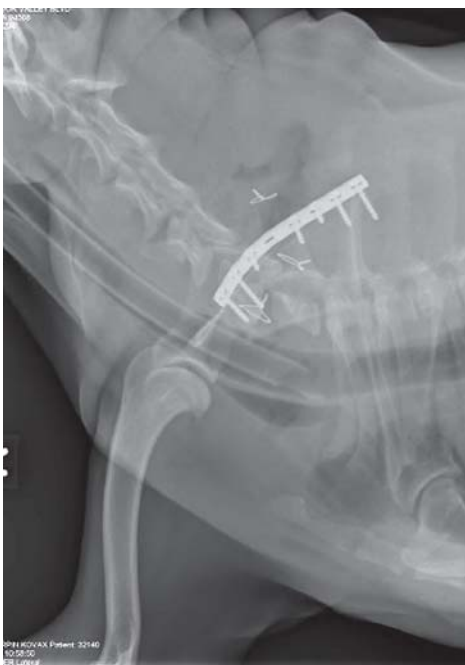On day 16 after presentation, Kovax returned for a seroma that had developed as a result of the motion at the scapular fracture site. Kovax remained minimally ambulatory on the right front limb. Kovax was seen by Dr. Greg Marsolais where under a brief anes-



**Figure 3**

thetic a nonhealing pocket wound on the side of the left tibia was excised and primarily closed. Additionally, over a liter of serosanguinous fluid was drained from the seroma and a thoracic bandage was placed to eliminate dead space. The coxofemoral luxation remained stable and testing indicated significantly improved hematologic and cardiovascular systems.

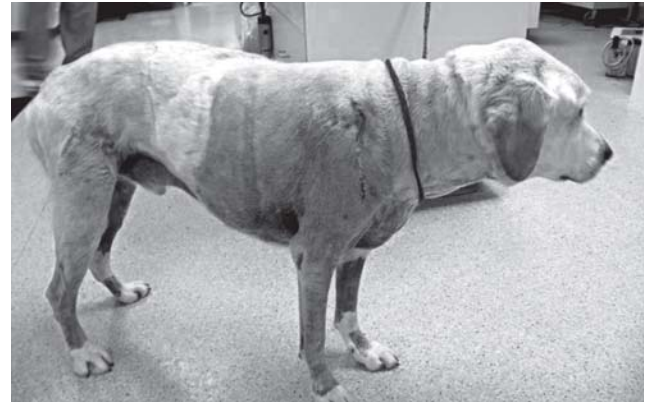On day 21, Kovax returned for drainage of another liter of fluid from



**Figure 4**

the seroma site over the scapular fracture as well as continued minimal weight bearing lameness of the right front limb. At that time, the owners elected open reduction and stabilization of the comminuted scapular fracture. Drs. Haburjak and Marsolais combined their expertise to successfully repair the scapular fracture with a bone plate, several screws, and interfragmentary wires (see Fig. 4). By the following morning, Kovax was ambulating well on all four limbs. After his suture removal two weeks later, he began intensive aquatic rehabilitation with the owners in their backyard pool. To this day, he continues to improve and the owners remain ecstatic with Kovax' recovery (see Fig. 5).

This case is a beautiful example of the collaborative efforts and 24-hour continuity of doctor care that you can continue to expect from the addition of Veterinary Surgical Centers of the Delta to VetCare Emergency and Specialist Care Center. On behalf of all three services, we sincerely look forward to serving your referral and emergency needs.



**Figure 5**

## NEWS *Notes*

### **VetCare Acquires New Videoendoscope**

In March of 2006, VetCare purchased a new video gastroscope. The image far surpasses that of our older fiberscope, and biopsies will be larger as the scope is larger in diameter. Dr. Kipperman is very happy with our new toy!

### **VetCare Upgrades Ultrasound Machine**

As of July 2006, we are now using an Aloka ProSound 4000 with color doppler and dicom compatibility. This new unit allows for better depth in larger dogs, and also is compatible with storing images digitally, as we do with our radiographs.

### **VetCare On Television**

During the heat wave this summer, the San Francisco affiliate of CBS news interviewed Dr. Kipperman and our nursing staff regarding prevention of heat stroke. Dr. Kipperman's pug, Winston, hammed it up on camera during his interview.



7660 Amador Valley Blvd  
Dublin, CA 94568

Phone: 925-556-1234  
Fax: 925-556-1229  
Email: [shvetcare@yahoo.com](mailto:shvetcare@yahoo.com)  
Web: [www.EmergencyVetCare.com](http://www.EmergencyVetCare.com)

Barry Kipperman, DVM, DACVIM  
Beth Custalow, DVM  
Gerardo Martin DelCampo, DVM  
River May, DVM  
Cheryl Ramos, DVM  
Britta Revels, DVM

John J. Haburjak, DVM  
Gregory S. Marsolais, DVM, MS  
Kimberly Carlson, DVM

*Please join us as VetCare hosts a free continuing education dinner for veterinarians*

## **New Approaches To Old Problems**

### **Medical and Surgical Management Of Collapsing Trachea The Role of the Nitinol Stent**

Presented by:  
John Haburjak, DVM, ACVS and Greg Marsolais, DVM, MS

### **Medical Laparoscopy**

Presented by:  
Barry Kipperman, DVM, ACVIM

**December 6<sup>th</sup> 2006, 7:00pm • Radisson Hotel  
6680 Regional Street Dublin, CA 94568**

RSVP by 2:00pm on November 27, 2006  
Contact: Susan Hatch at [shvetcare@yahoo.com](mailto:shvetcare@yahoo.com) or 925-556-1234

AAVSB Race Provider #68. This program was reviewed and approved by the AAVSB RACE program for continuing education. Please contact the AVSB RACE program at [race@aaavsb.org](mailto:race@aaavsb.org) should you have any comments/concerns regarding this program's validity or relevancy to the veterinary profession.